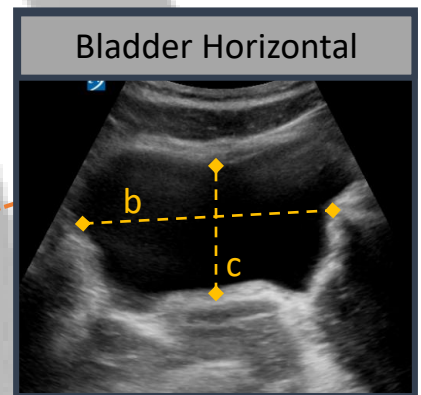
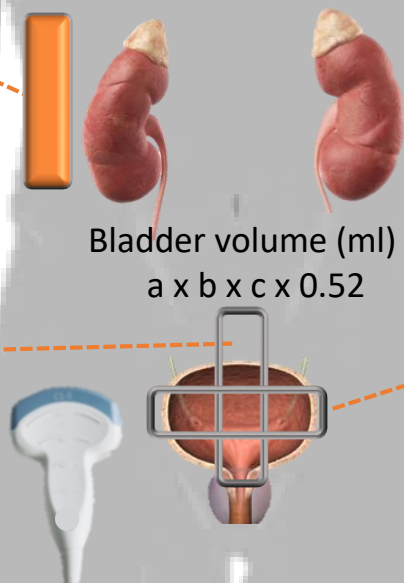
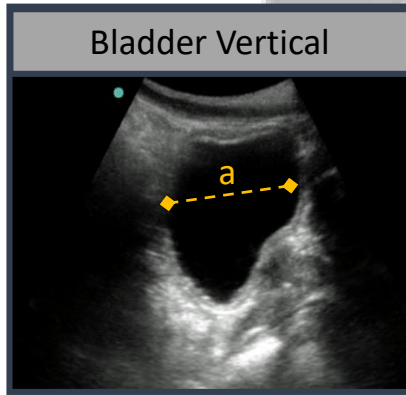
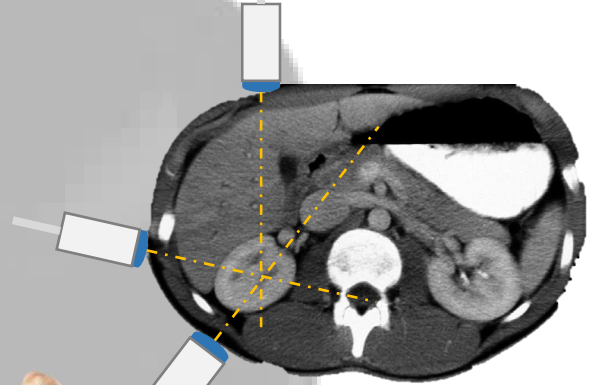
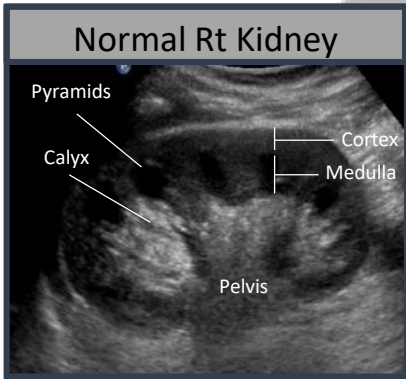


Renal Ultrasound



Hydronephrosis			
Mild	Moderate	Severe	
Urine barely splits sinus	Full pelvis, major calyces dilated	Uniformly dilated minor calyces, parenchyma spared	Parenchymal compromise

Timberlake, Matthew D., and C.D. Anthony Herndon. "Mild to moderate postnatal hydronephrosis --grading systems and management." *Nature Reviews Urology*, vol. 10, no. 11, 2013, p. 649+. *Academic OneFile*, Accessed 23 Apr. 2017