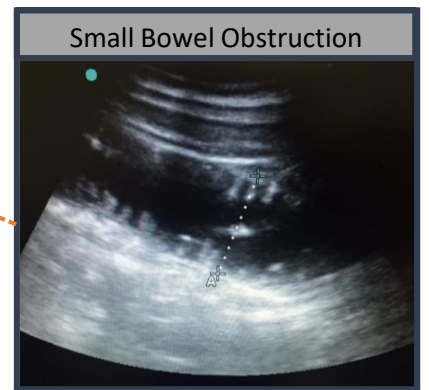
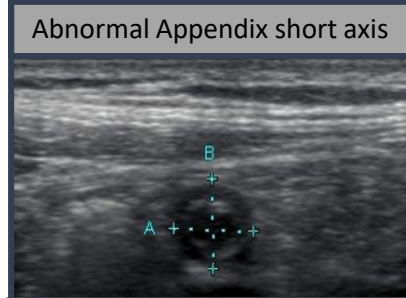
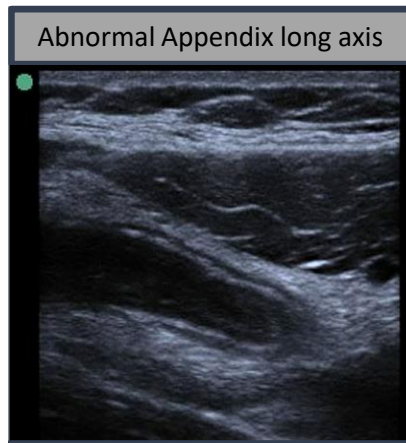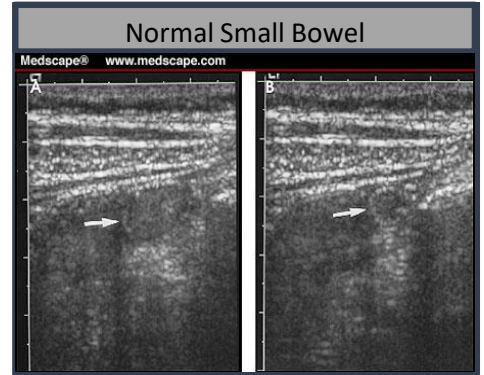
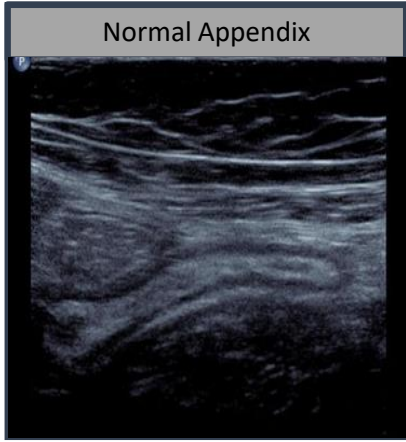



Acute Appendicitis & Small Bowel Obstruction



ABCD-EF mnemonic

- A. Activity (Ileus Vs Mechanical)
- B. Bowel Thickness > 3mm
- C. Colour Doppler
- D. Diameter > 3 cm
- EF. Extraintestinal Fluid

by Dr. Hadiel Azzam

Acute Appendicitis:

- Outer Diameter > 6mm
- Non-compressible
- No peristalsis

MAY also see:

- Appendicolith
- Increased vascularity with Color Flow Doppler
- Periappendiceal Fluid Collection

