

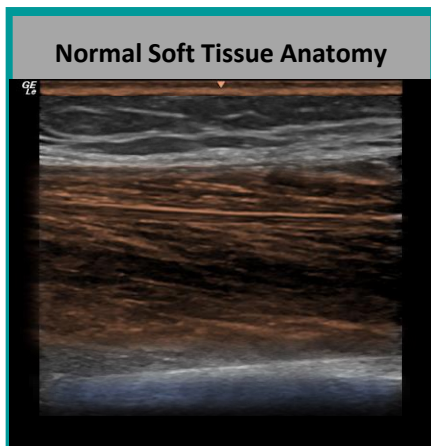
# Soft Tissue Scan

## Foreign Bodies and Infections

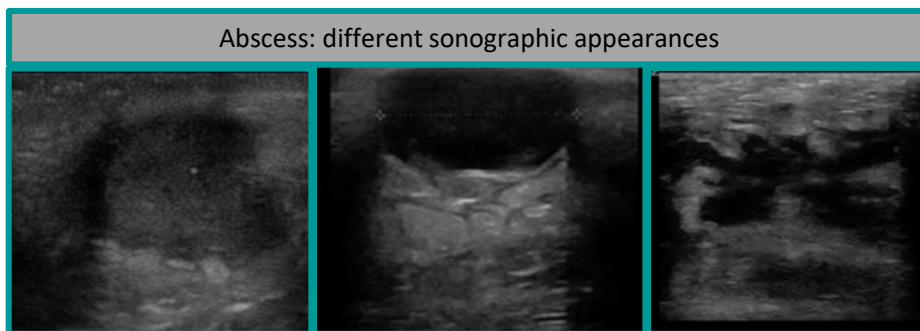
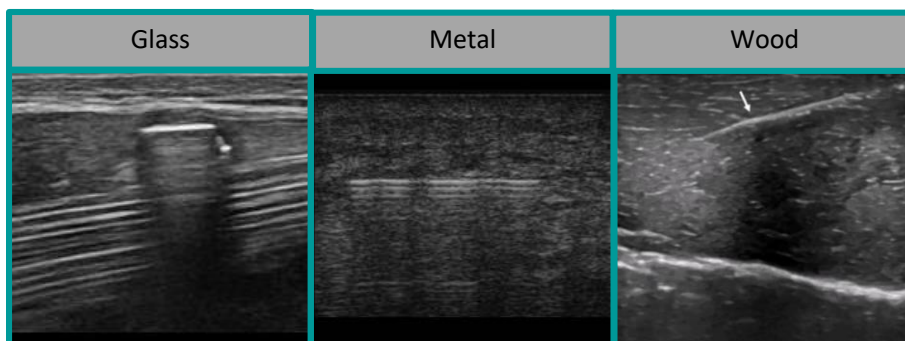


### Tips

- Scan from normal to normal area
- Apply Doppler when needed



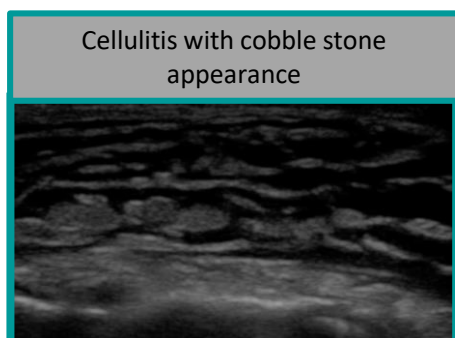
Skin: Epidermis + Dermis  
 Subcutaneous tissue  
 ← Fascia  
 Muscles  
 Bone



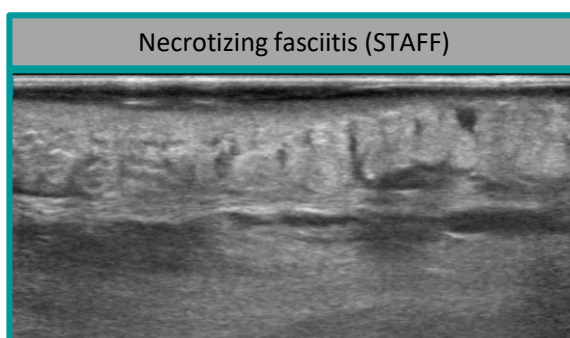Hypoechoic collection

Anechoic collection with posterior acoustic enhancement

Diffuse collection



Cellulitis with cobble stone appearance



Necrotizing fasciitis (STAFF)

Subcutaneous thickening  
 Air shadowing

← Fascial disruption & Sub-Fascial fluid

Images courtesy of Josef Minardi